

5th course of advanced surgery of the knee
Val d'Isère, 02-2014

Meniscal tears in children & young athletes.

Prof. Romain Seil, MD, PhD

Orthopaedic
Surgery

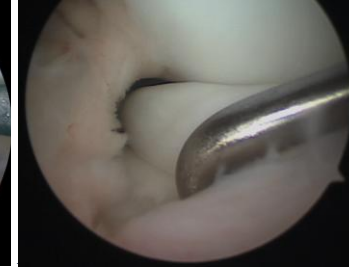
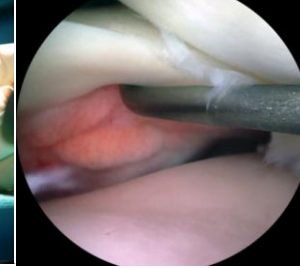
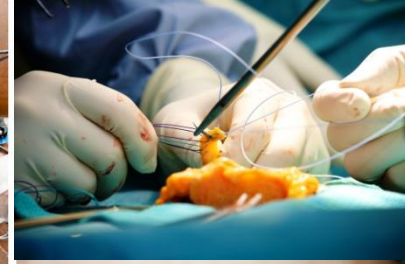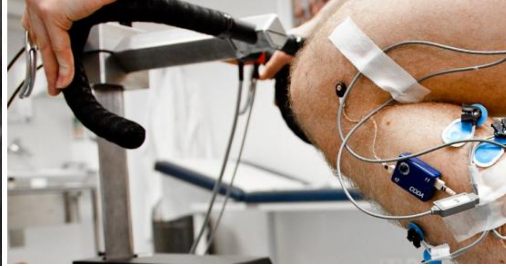

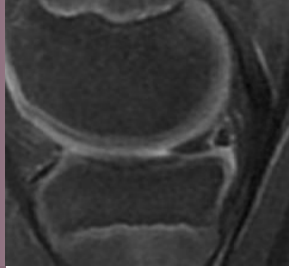
Centre Hospitalier
de Luxembourg

Sports Medicine
Research Laboratory



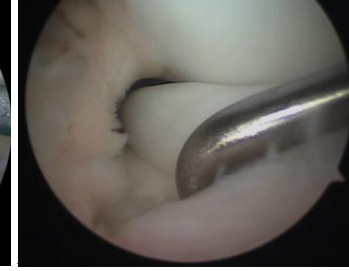
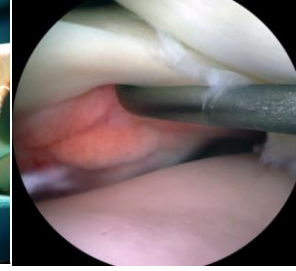
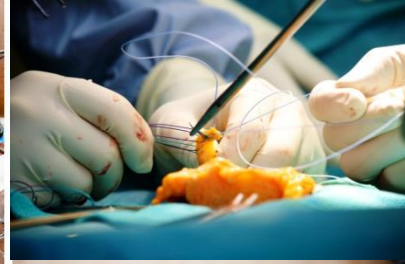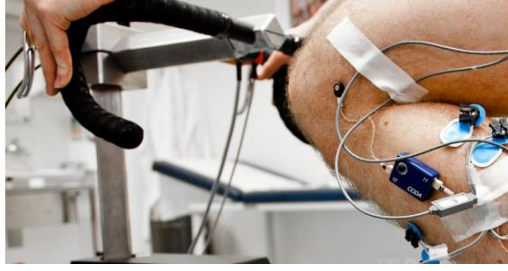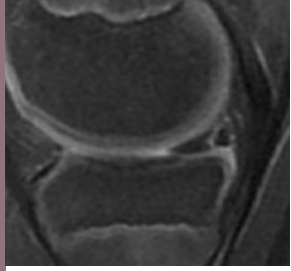Centre de Recherche
Public – Santé,
Luxembourg



The injured knee in the young athlete

- MAGNITUDE -

All injuries	4 years
Athletes (n)	≈ 241
Injuries (n)	1458
Injuries/athl./year	1,5
Knee (n)	311
% Knee	21%
Major - Knee (n)	81
% Major - Knee	6%



The injured knee in the young athlete

- Incidence of severe knee injuries: 8,2%
- Incidence of ACL injuries: 0,8 %
- Incidence of ACL injuries in general population: 0,8 ‰



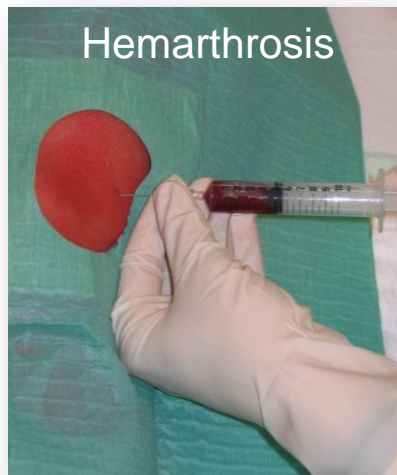
Frobell RB, Scand J Med Sci Sports 2007
Granat LP, Am J Sports Med 2009
Renstrom P, Br J Sports Med 2012



Courtesy of: P. Gicquel, Strasbourg, France

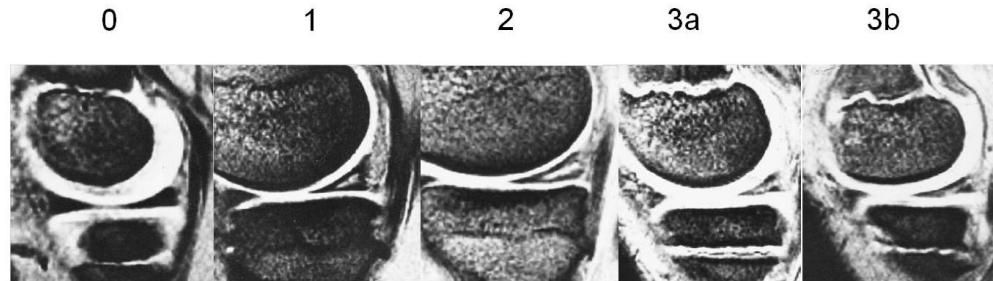- Pain & blocking > 90%
- Elastic extension deficit

Bergerault F, 2006



- 1/3 ligamentous lesions (♂ > ♀)
- 1/3 patellar dislocations (♀ > ♂)
- 1/3 meniscus lesions

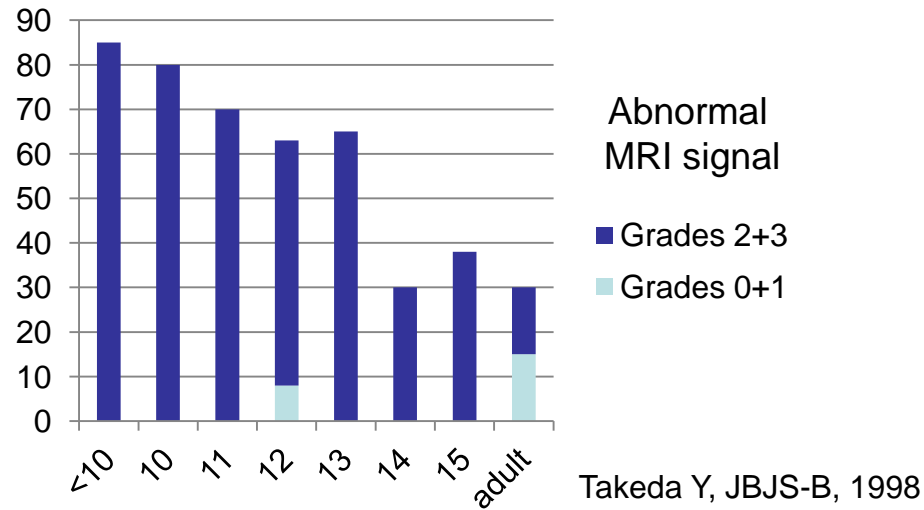
Luhmann SJ, 2003




63 % 2 % 22 % 11 % 2 %

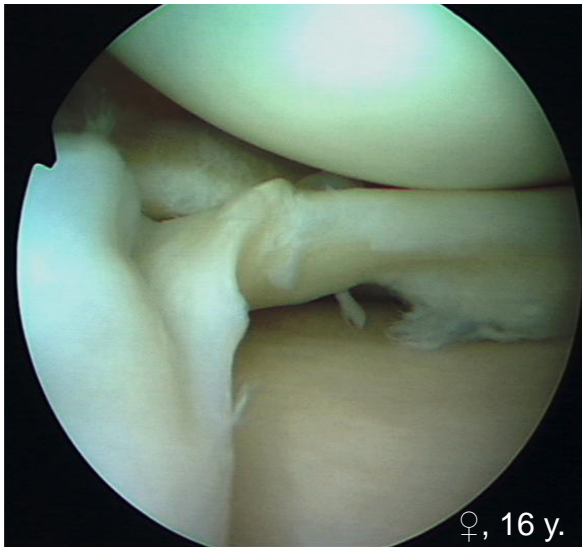
Beware of false positives !

Takeda Y, JBJS-B, 1998
Cruess JW, Radiology, 1987





- > 50 % sports injury
 - 45 % combined with ACL tear
 - 55 % isolated
 - some congenital
-
- Vertical 83 %
 - Horizontal 13 %
 - Radial 3 %



1. Association with ACL tears

- instabilities (lateral)
- meniscosynovial (medial)

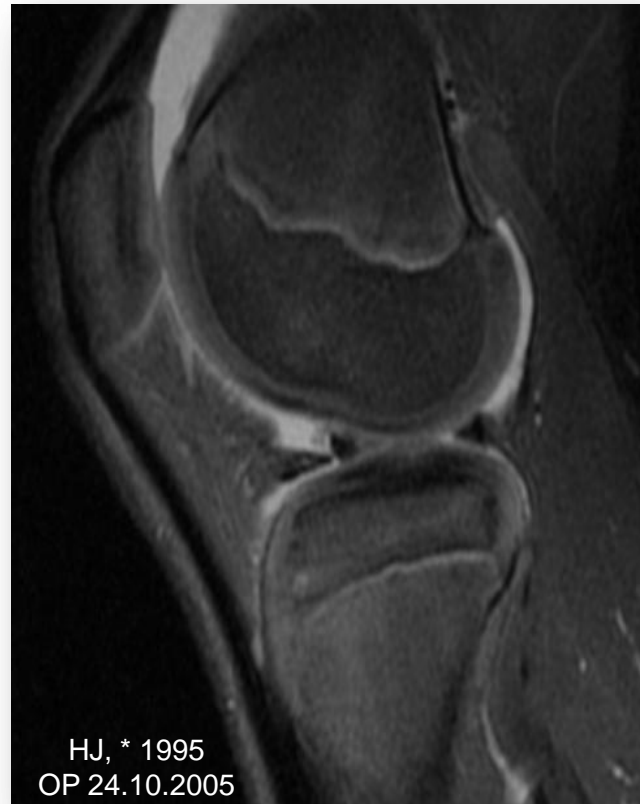2. Isolated lesions on stable knees:

- bucket handle, flap
- radial tears lateral meniscus
- isolated root tears
- meniscal ossicle
- instabilities lateral meniscus
- horizontal tears

3. Congenital abnormalities

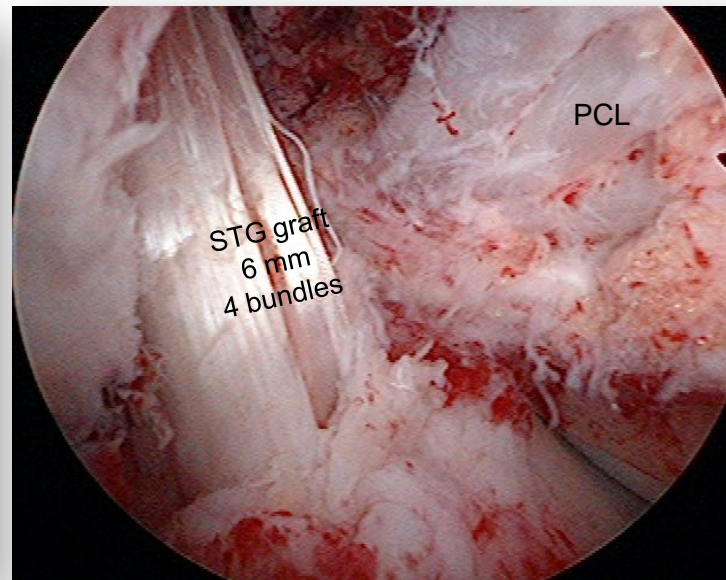
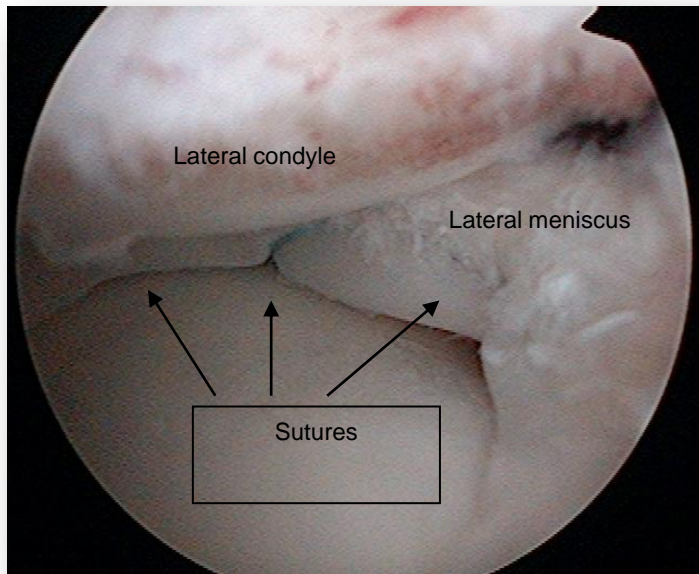
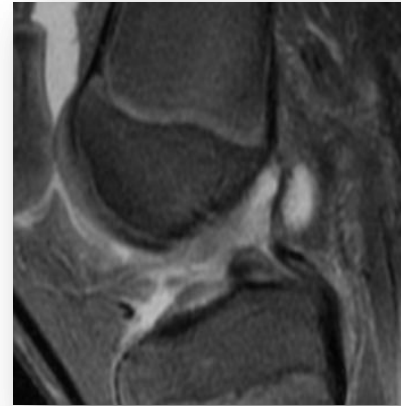
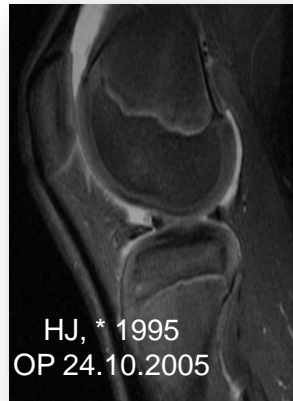1. Association with ACL tears & open physes

Referred for meniscus tear

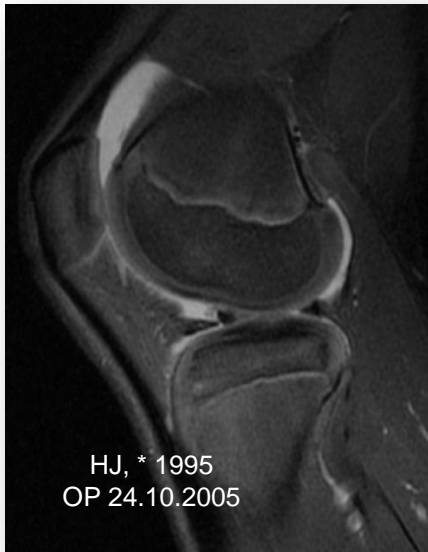

- ♂ 11 y.,
- Football injury
- Extension deficit

1. Association with ACL tears & open physes



1. Association with ACL tears & open physes



Primary:

36 - 100 % of acute ACL tears

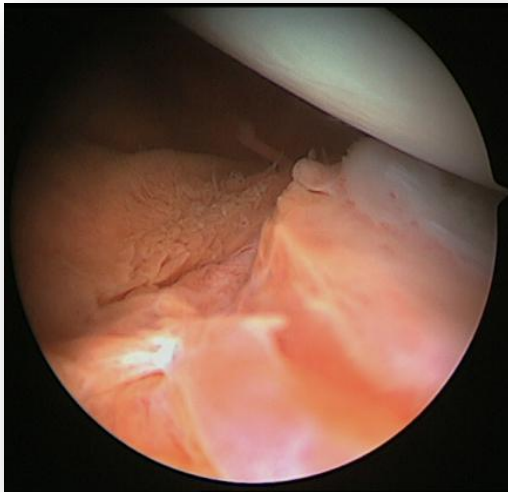
Lipscomb AB 1986;
Bracq H 1996;
Andrews M 1994

Secondary:

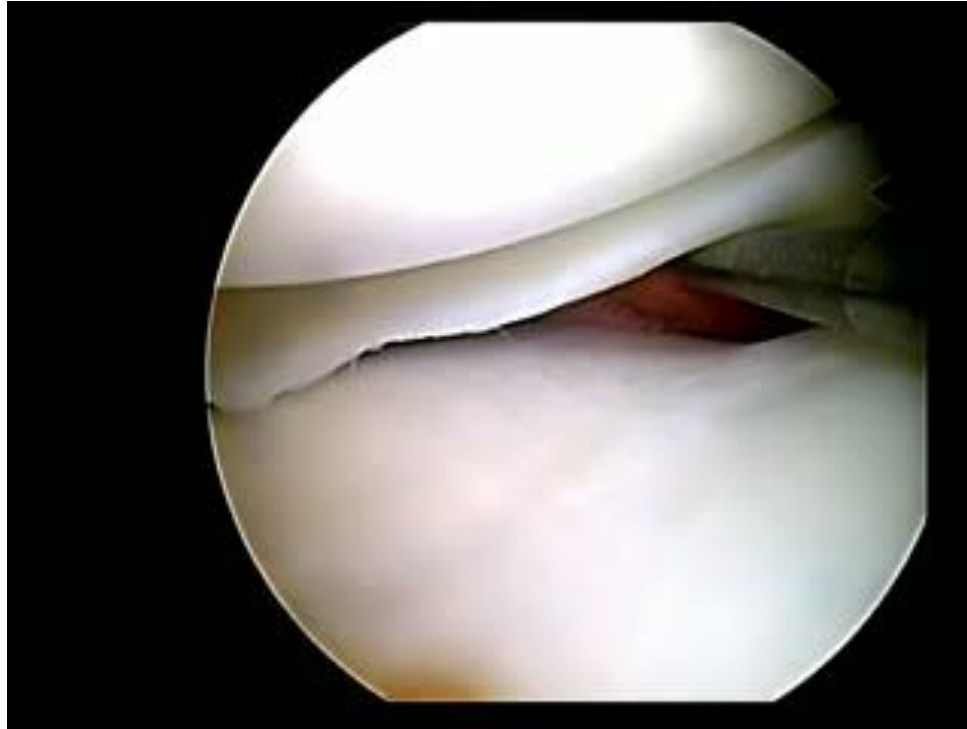Medial meniscus

Within 1st year after injury

Millett PJ 2002
Henry J 2009

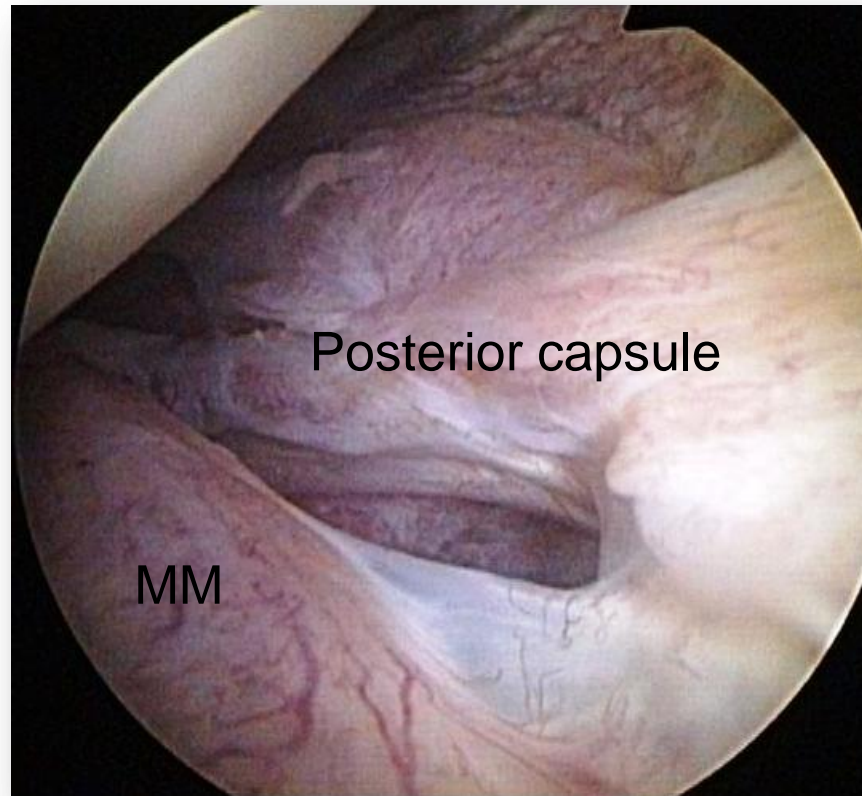


Lateral meniscus



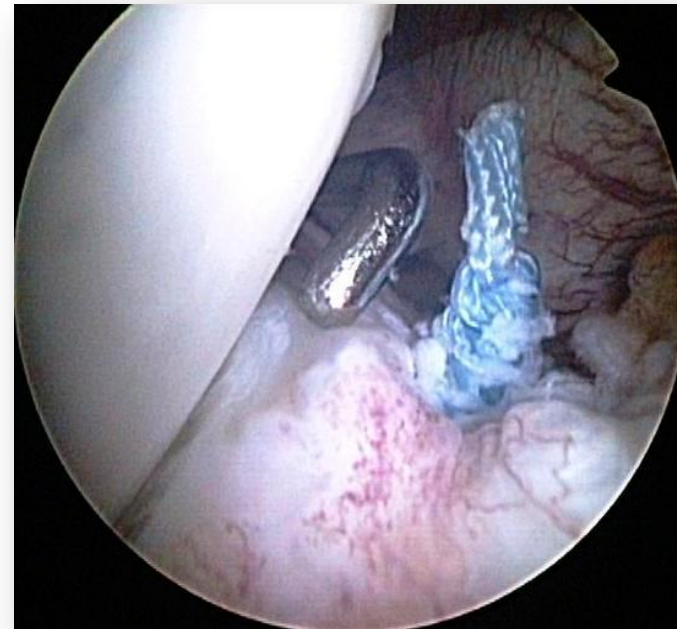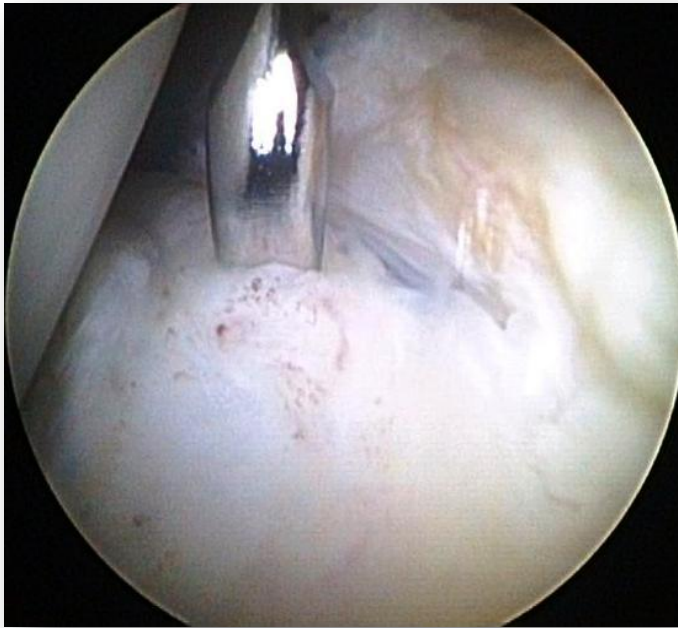- ♂ 15 y. football
- closed physes
- ACL & lateral meniscus repair

Medial meniscus



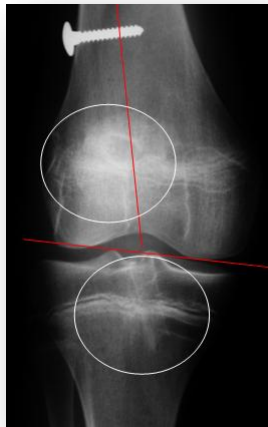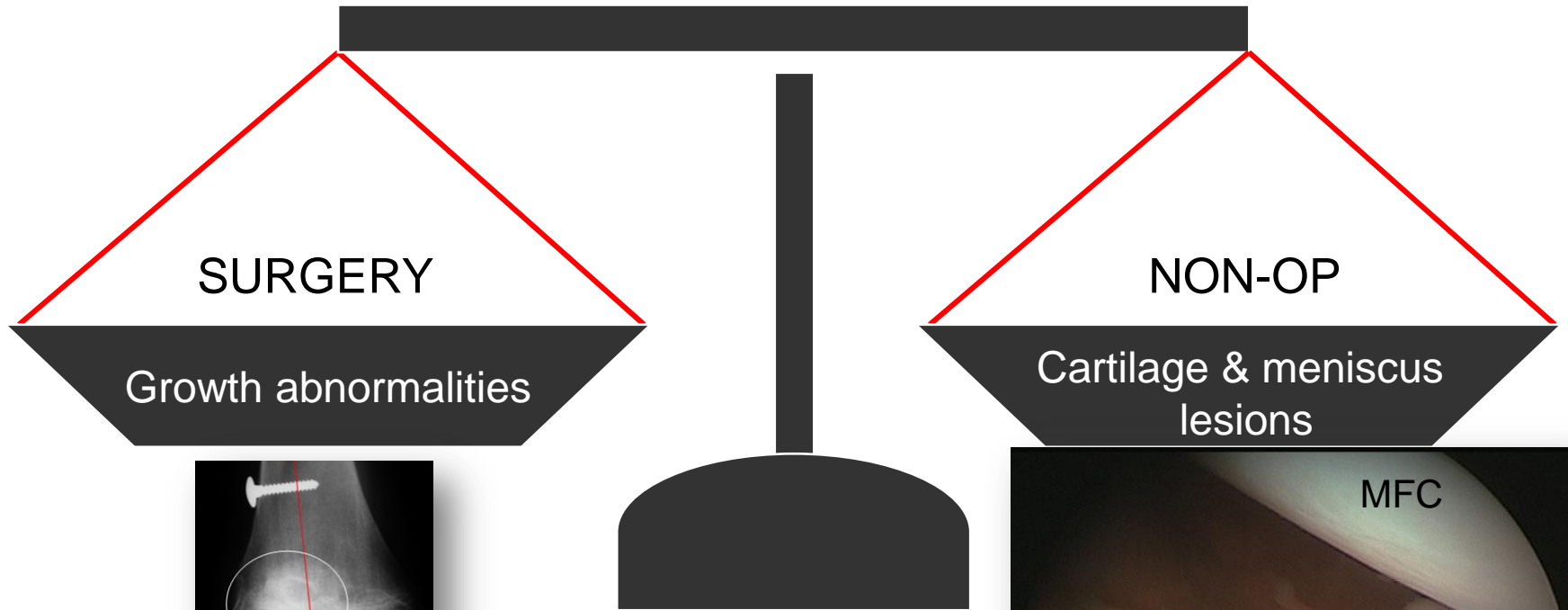
- ♂ 14 y. football
- open physes
- ACL & medial meniscus repair

Medial meniscus

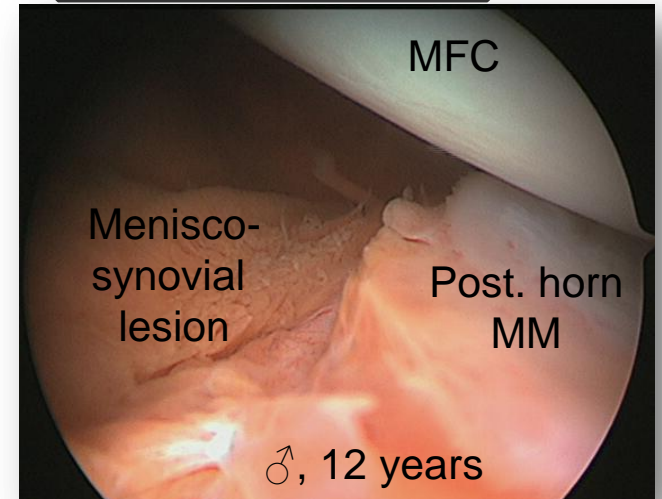


Associated to 15 %
of our ACL reconstructions !

Should they be operated systematically ?



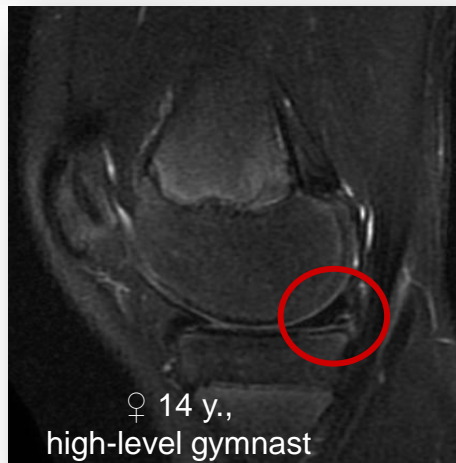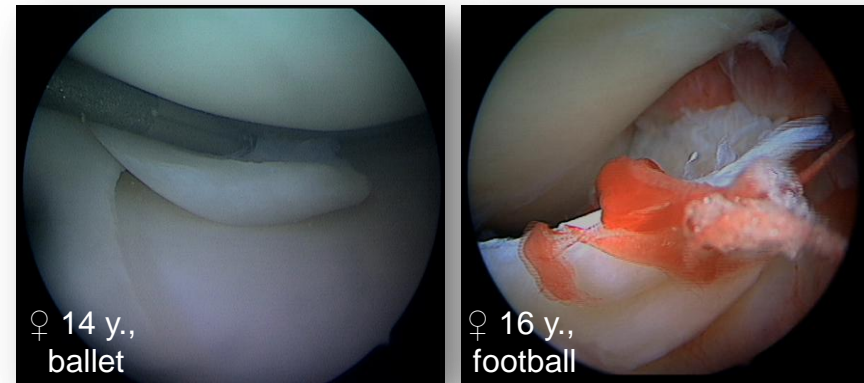
Courtesy of C. Bonnard,
Tours, France




No international consensus on indication for surgery,
expert-opinion level discussions

- Operate if dislocated bucket handle tear
- Push indications for repair
- Never do isolated repair without stabilization

(Exception: acute bucket handle & inflammation)



- Frequently isolated (55 %)
- Related to increased physiologic laxity ?
- Always try to repair !



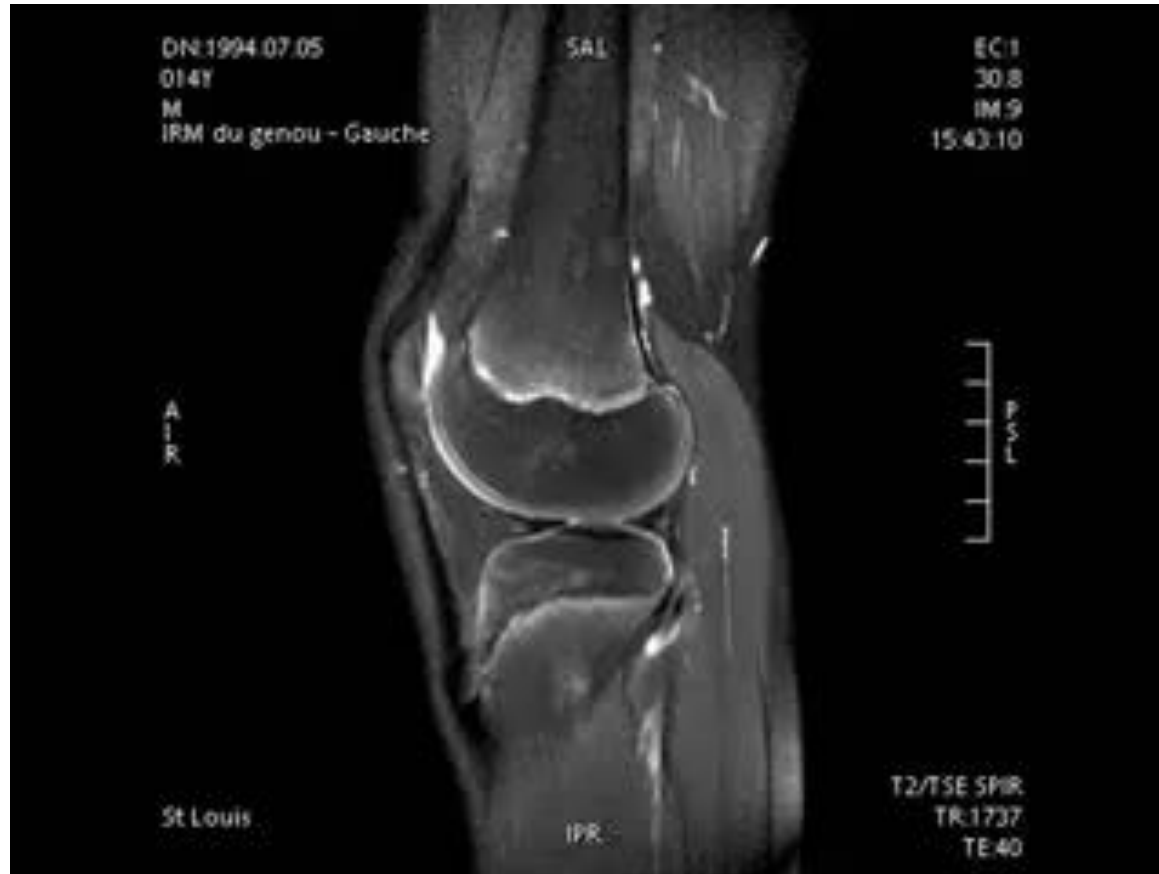- Usually isolated
- Functional complete meniscectomy
- Repair to restore stable rim
- 50 % healing rate

♂ 15 y., football, stable knee

- painful locking in flexion
- can mimick patellar subluxation
- MRI normal
- can resolve spontaneously

2.

Instabilities of the lateral meniscus



- ♂ 15 y. football

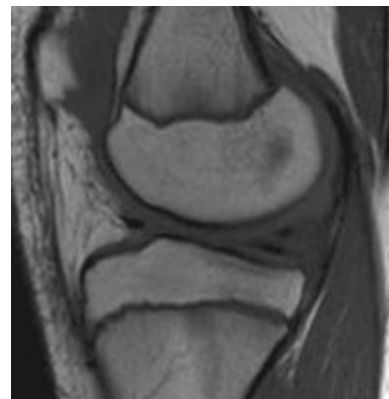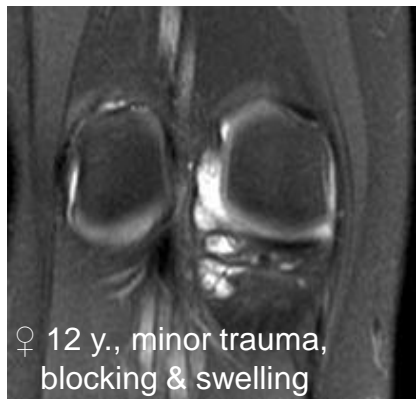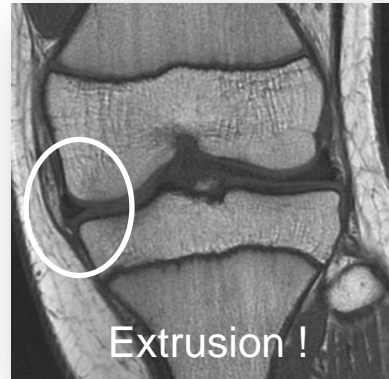
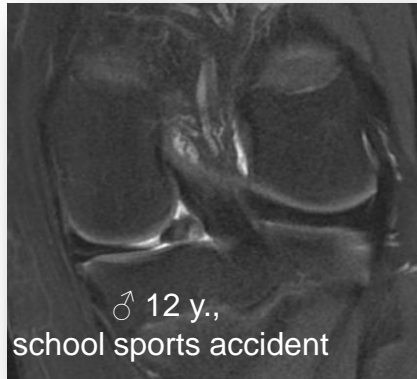Simonian PT, Arthroscopy 1997

George M, Arthroscopy 2003

Garofalo R, KSSTA 2005

2.

Meniscal root tears - Meniscal ossicle

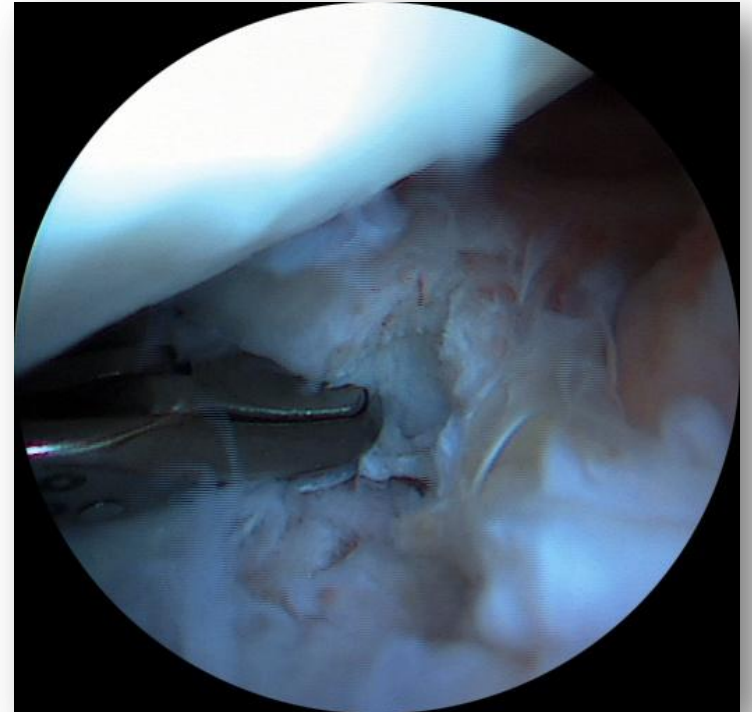
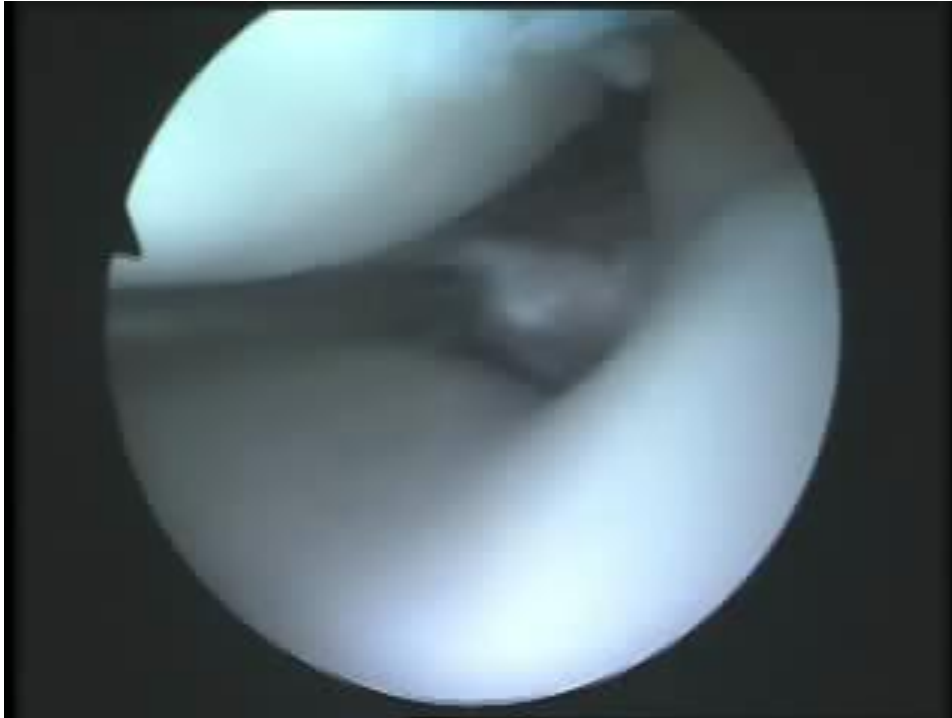


- Traumatic (minor)
- Isolated
- Combined with ACL agenesis or traumatic ACL tear

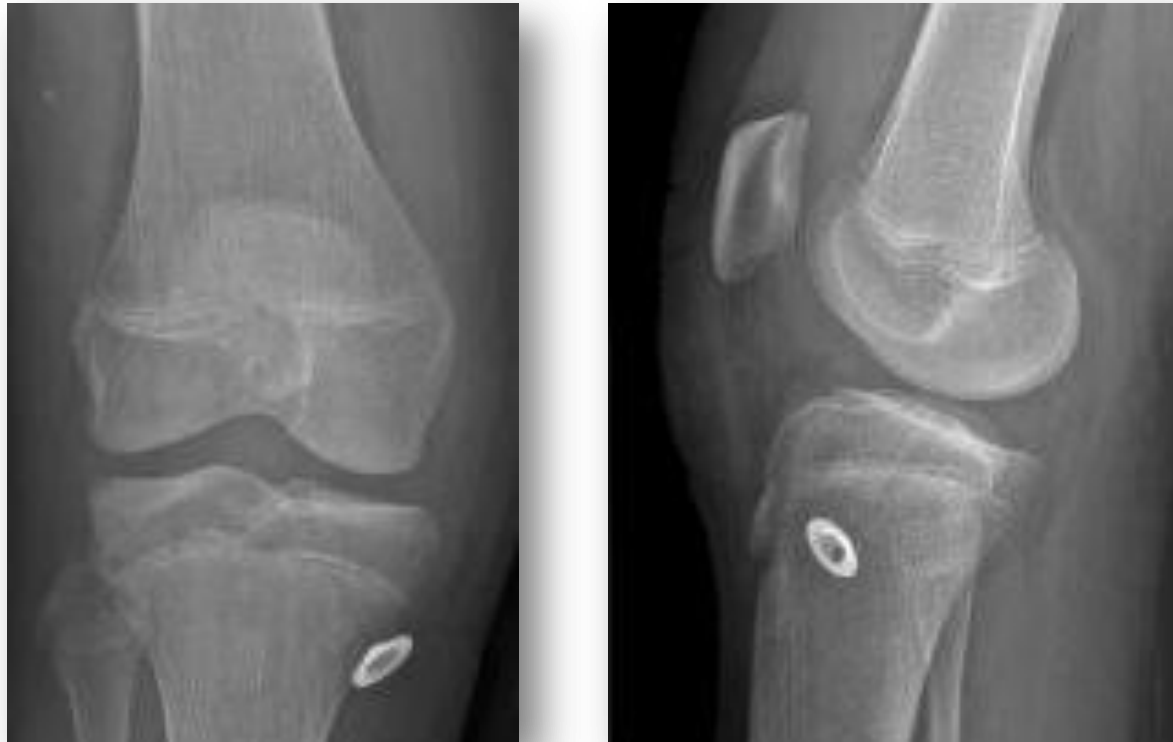Berg E, 1991; Pagnani MJ, 1991
Raustol OA, 2006; Griffith CJ, 2008; Marzo JM, 2009

2.

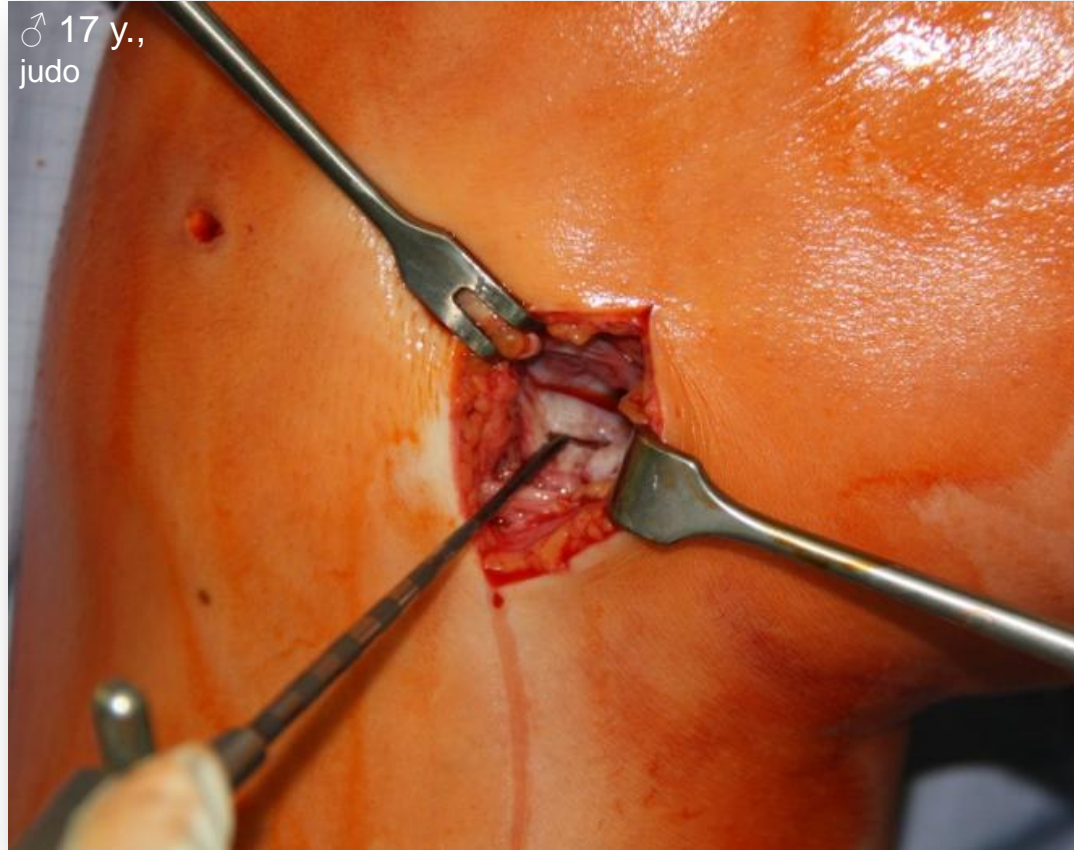
Meniscal root tears - Meniscal ossicle

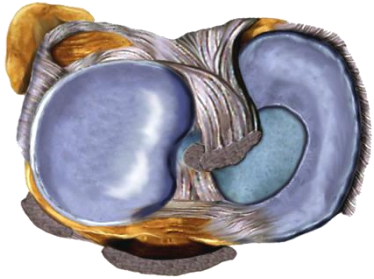


♀ 12 y, minor trauma, recurrent swelling, blocking

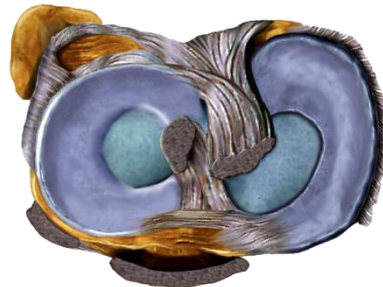

♀ 12 y, minor trauma, recurrent swelling, blocking

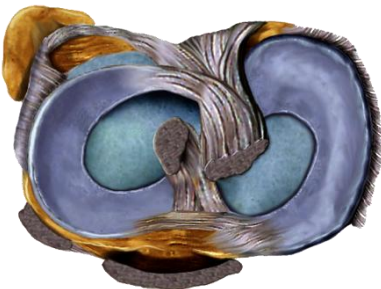



Complete (70-80%)

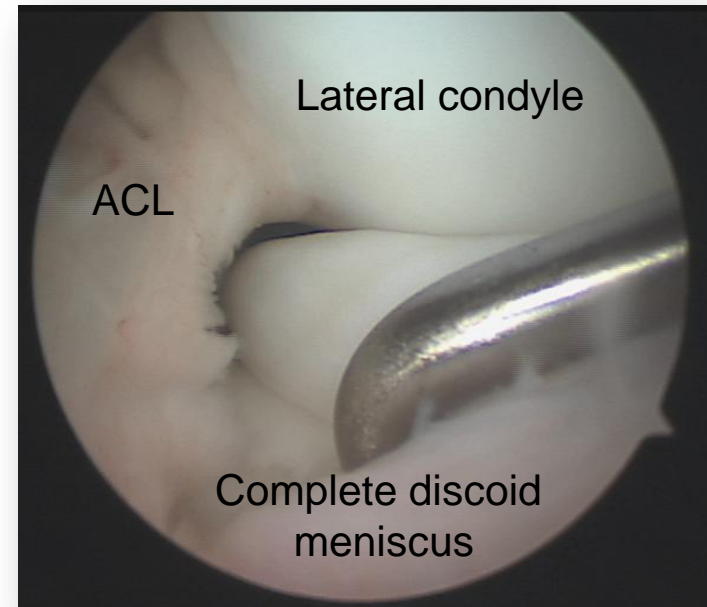


Incomplete (10-25%)

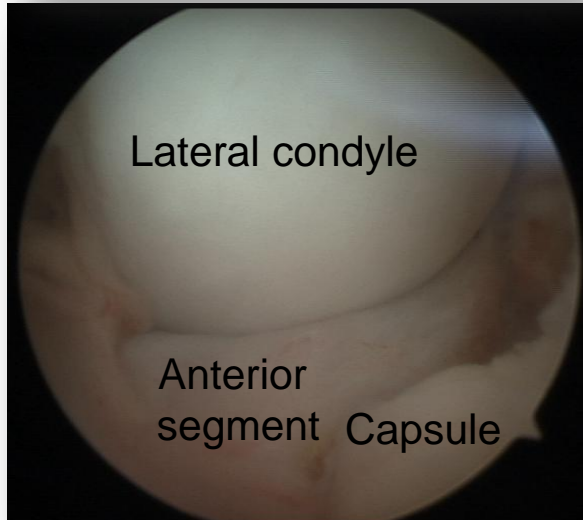
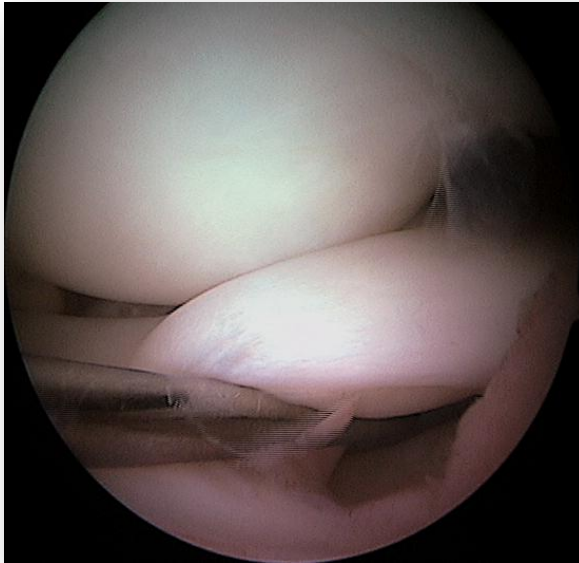

Wrisberg type (< 10 %)

Watanabe M, Takeda S, Ikeuchi H. Atlas of arthroscopy. Tokyo: Igaku-Shoin, 1978;88.

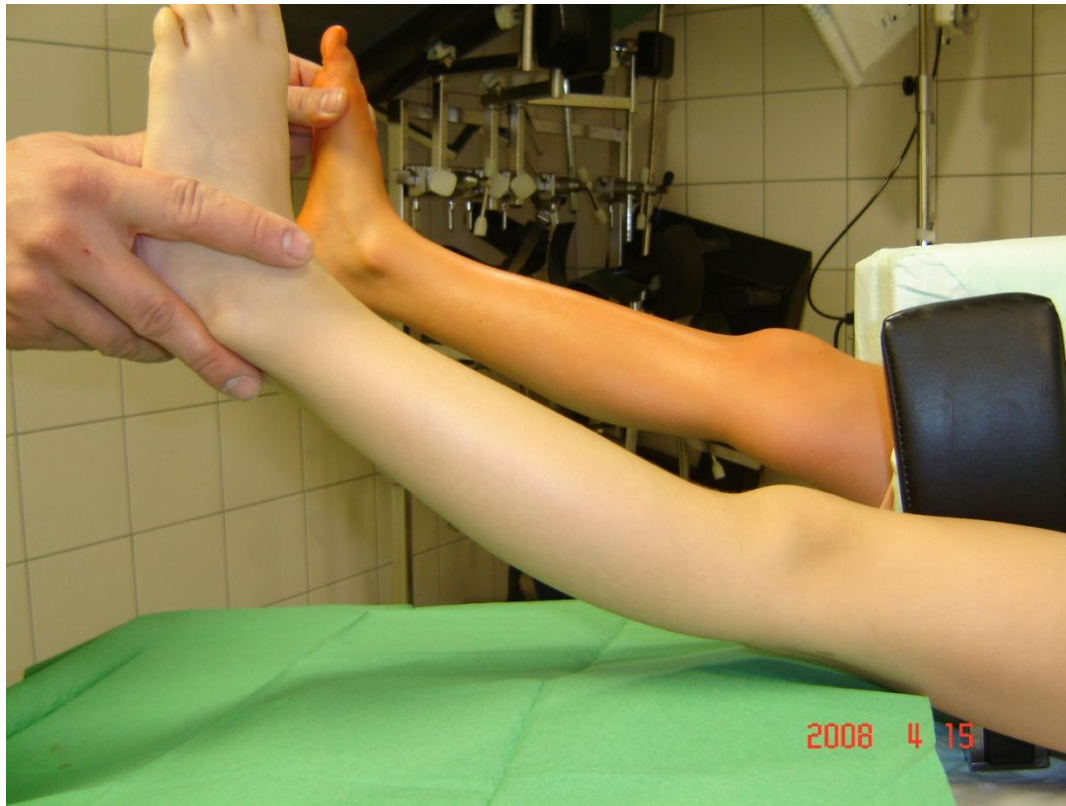

- ♀ 12 y, ballet
- blocking, extension deficit, crepitations



- Peripheral instabilities 28-77 %
- More frequent withn complete type

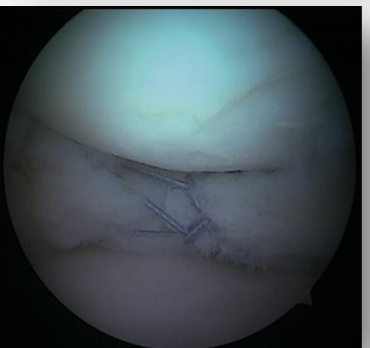
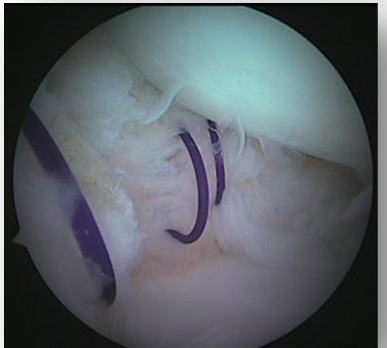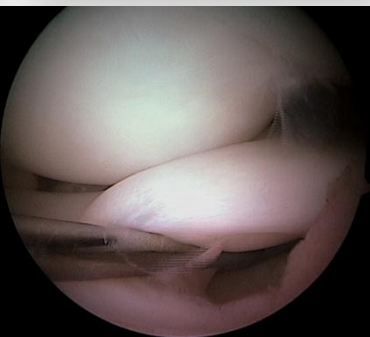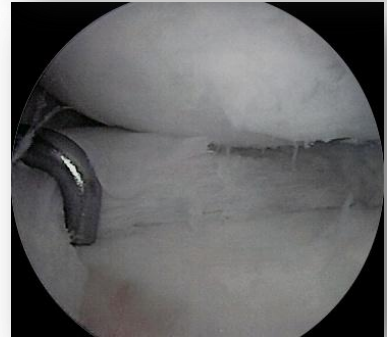
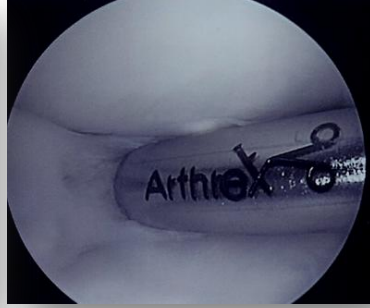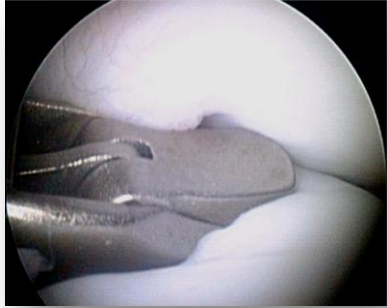- Anterior 47-53 %
- Middle 11 %
- Posterior 39 %



♀ 5 y, extension deficit

3.

Lateral discoid meniscus

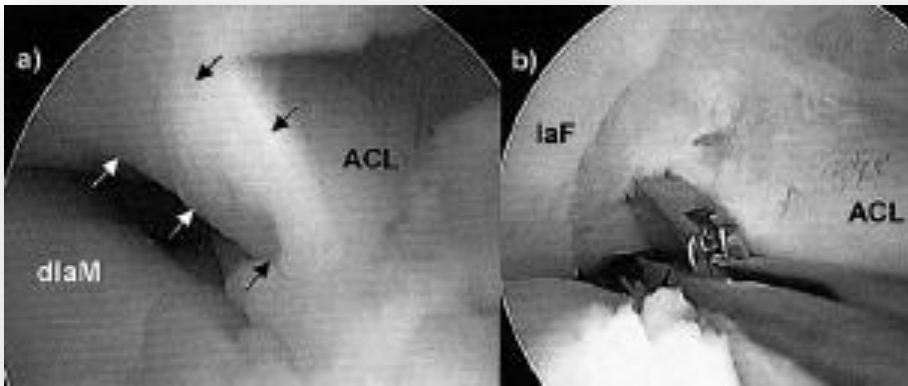


1. Partial meniscectomy (saucerization)
Beware: tight knees
(avoid sectioning into popliteal space)

2. Stability testing

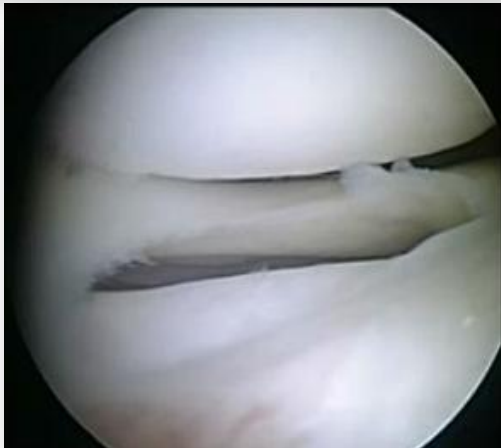3. Repair of detached or unstable fragment

Good CR, 2007
Klinge KE, 2004



- Cord-like structure between ACL and meniscus
 - ♀ 5 y., painful blocking

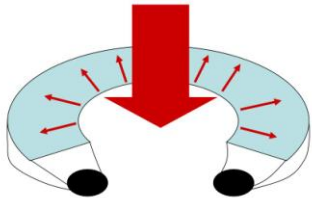
Laprell H, Arthroscopy 2007



- Circular meniscus & ACL agenesis
 - ♀ 14 y., recurrent swelling

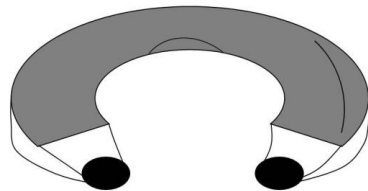
Rehab: functional classification

Axial
compression

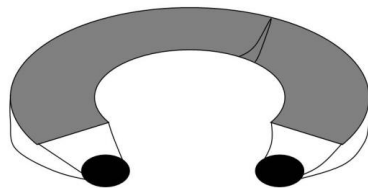


CLASSICAL 90
%

Tears of the meniscal body

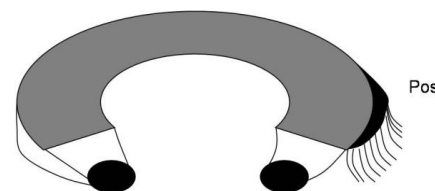


Radial tears

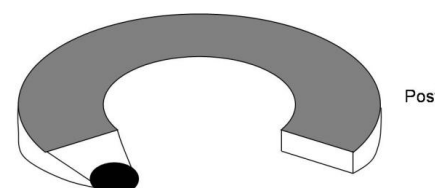


Non-classic 10 %
Periphery

Meniscosynovial tears



Meniscal root tears



Weight
bearing

6 weeks

No weight
bearing

- 1986 – 2008: 14 publications
- 309 lesions 277 repairs
32 abstentions / debridements

Repair results (level of evidence IV):

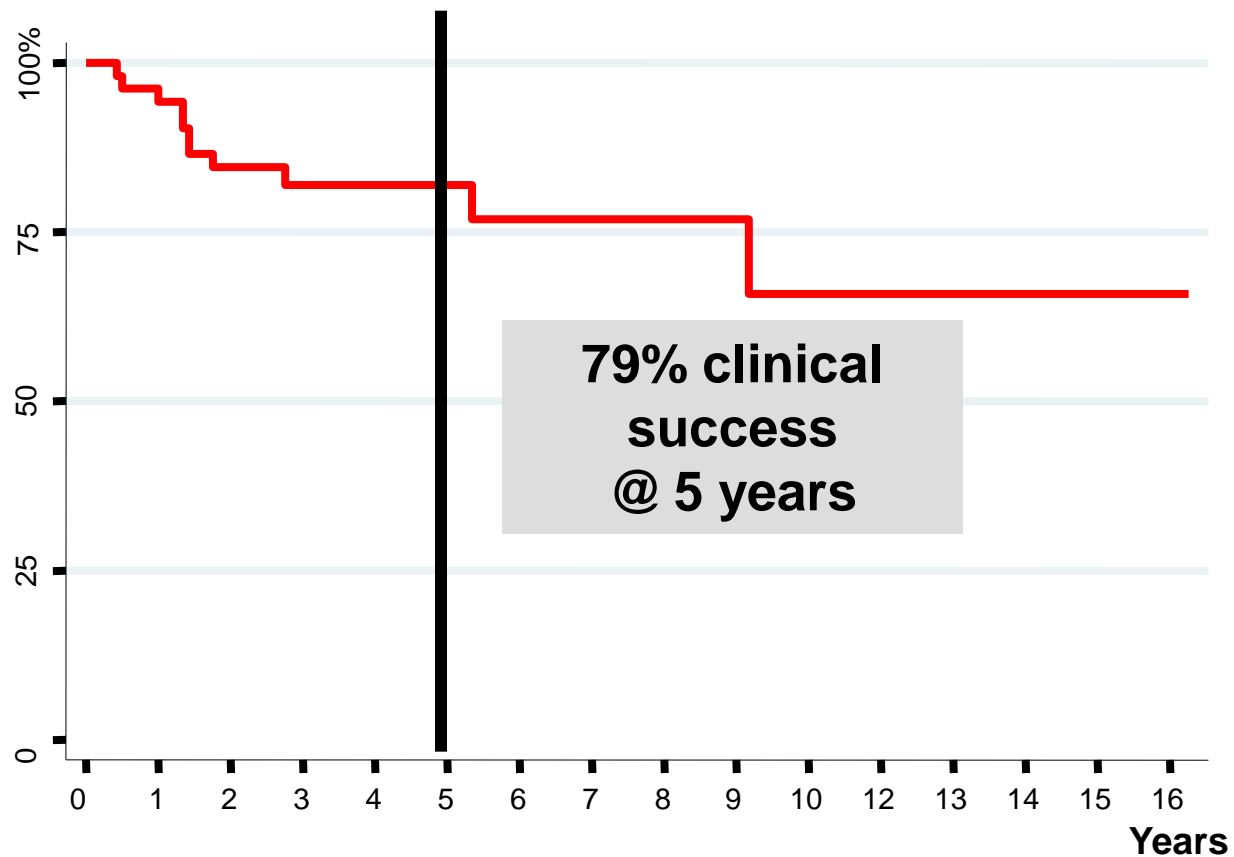
Retrospective series

Scott JBJS Am 1986
Cannon AJSM 1992
Mintzer AJSM 1998
Bloome Arthroscopy 2000
Noyes AJSM 2002
Symposium SFA 2003
Bergerault Ann Orthop Ouest 2004

Case reports

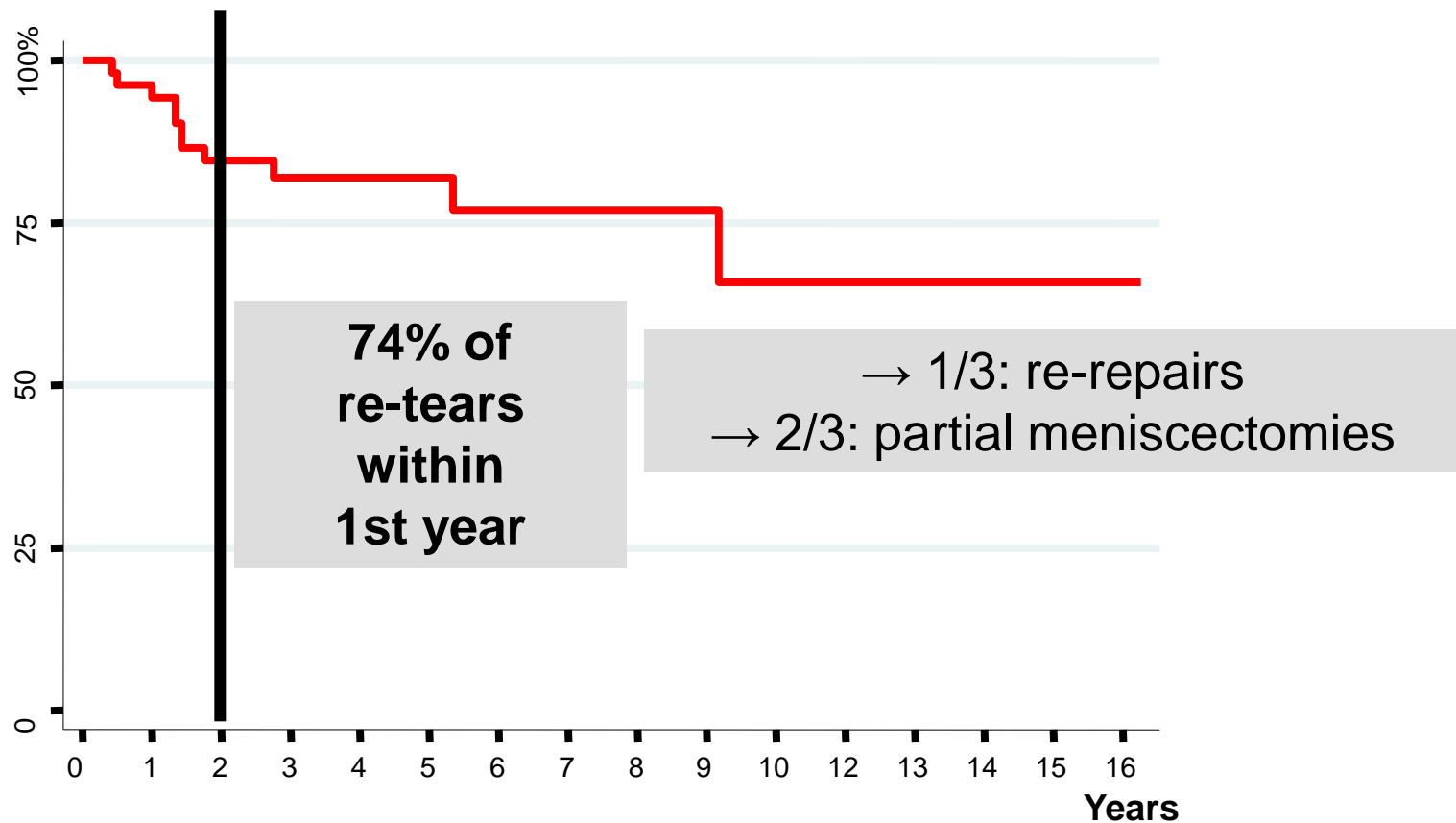
Graf Arthroscopy 1992
Mizuta JBJS Br 1995
Aichroth JBJS Br 2002
Fuchs Arthroscopy 2002
Millett Arthroscopy 2002
Anderson JBJS Am 2003
Vaquero CORR 2005

Meniscus preservation

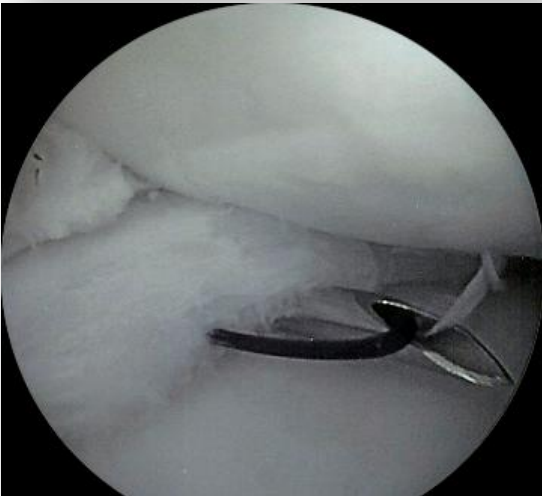
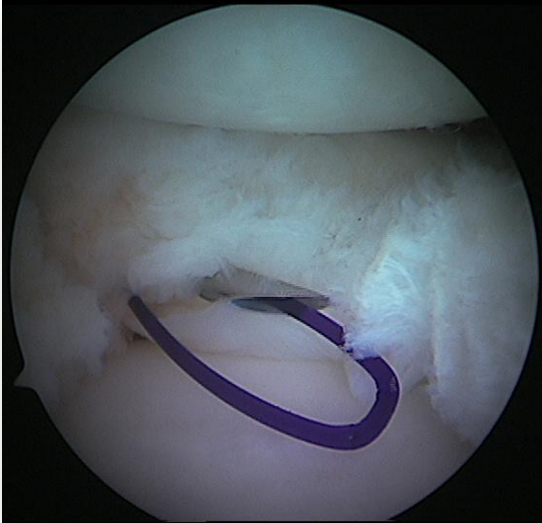


Accabled F, Bergerault F, Rev Chir Orthop, 2007

Meniscus preservation

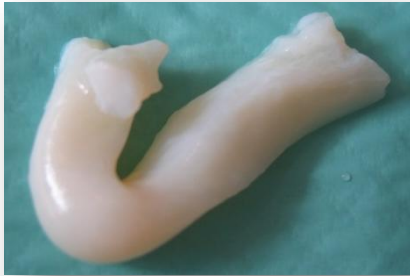

Accabled F, Bergerault F, Rev Chir Orthop, 2007

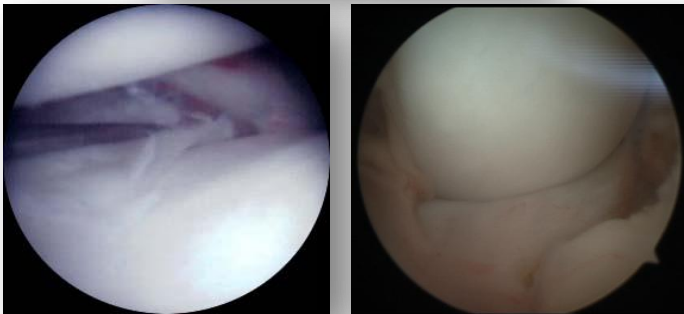


- Avoid resections
- Repair: 75% success rate
- Do not miss ACL tear
- Stabilise knee
- Immobilize after repair
- Symptomatic discoid meniscus:
saucerisation + repair

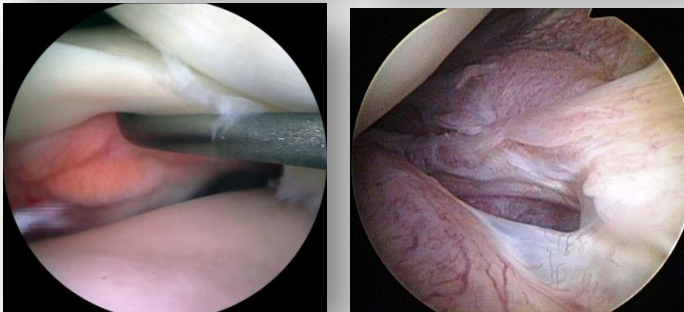
Key points & future evolution



- Some rare bucket handles still have to be resected → need for early diagnosis

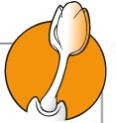

- Repair of radial tears
- Stabilize discoid menisci



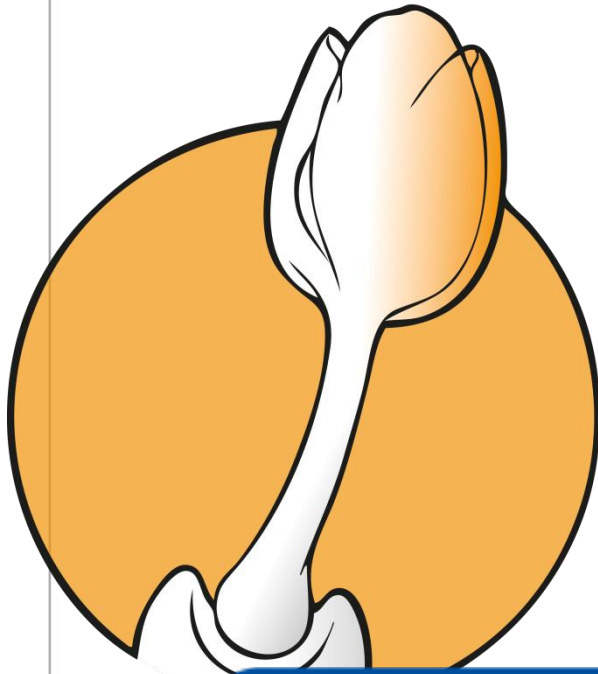
- More evidence needed on specific tears

AMSTERDAM / THE NETHERLANDS



16th ESSKA Congress

May 14-17, 2014



CONGRESS PRESIDENT
C. Niek van Dijk

ESSKA PRESIDENT
João Espregueira-Mendes

SCIENTIFIC CHAIRMEN
Stefano Zaffagnini
Roland Becker
Gino Kerkhoffs

ORGANISER
esska@intercongress.de



www.esska-congress.org