

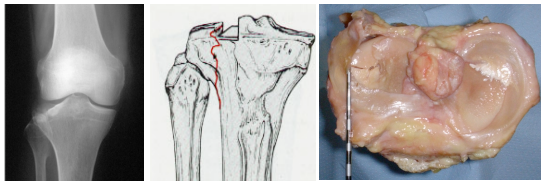
# Split Tibial Plateau Fractures

Ned Amendola MD  
Davide Bonasia MD


 University of Iowa  
Sports Medicine Center

## Epidemiology

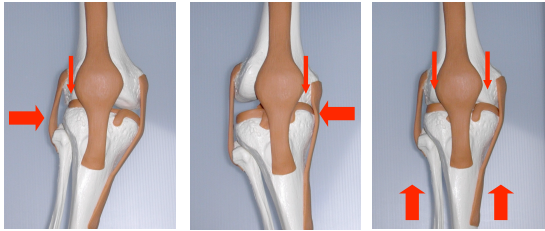
Tibial plateau fractures: 1% of all fractures




Lateral plateau > Medial plateau  
(55-70%)



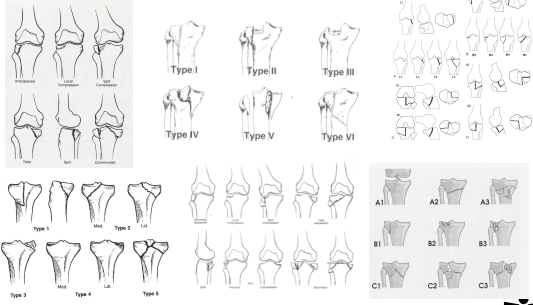
## Traumatic Mechanisms




1) Valgus Forces    2) Varus Forces    3) Axial Loads

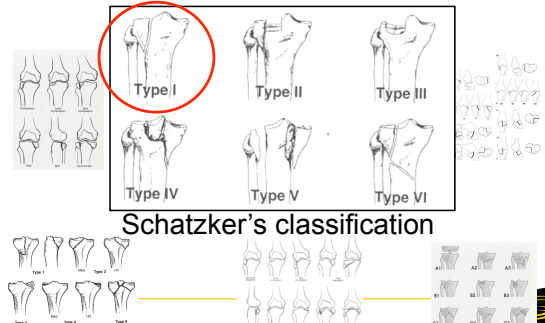


## Classifications






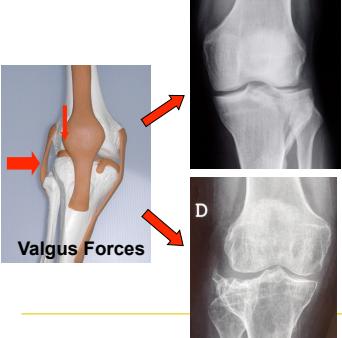
## Classifications



Schatzker's classification




## Split fracture (Schatzker type I)





**SPLIT**  
Younger patients, good bone quality, higher energy trauma. Frequent associated lesions

**DEPRESSION**  
Older patients, poor bone quality, low energy trauma. Rare associated lesions



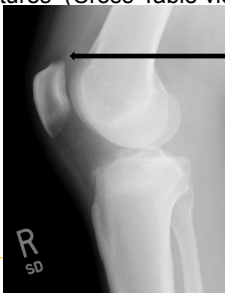
### Diagnosis

- Standard AP and Lateral Rx (+ oblique)





### Diagnosis

- Fat-Blood-Interface (FBI sign) in intrarticular fractures (Cross-Table view)

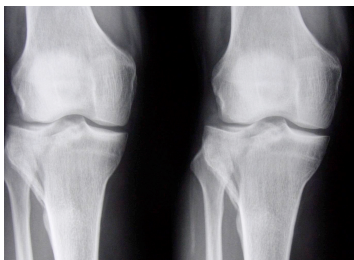



FBI sign



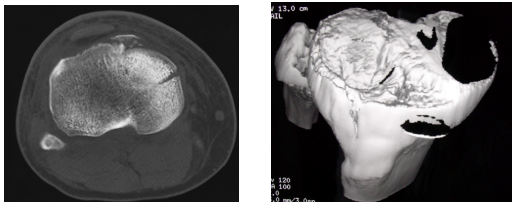

### Diagnosis

- Classic Tomography (to assess the diagnosis)

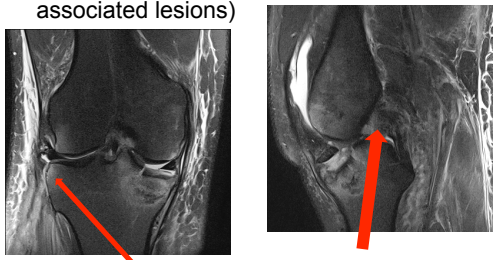
### Diagnosis

- CT scan (Essential in determining the fracture pattern)


### Diagnosis

- MRI (to assess associated lesions)



Lateral / PL avulsion


PCL injury



### Associated injuries

- Meniscal tears occur in up to 50% of tibial plateau fractures.
- Associated ligamentous injury to the cruciate or collateral ligaments occurs in up to 30% of tibial plateau fractures (mainly in young adults).
- Fractures involving the medial tibial plateau are associated with higher incidences of peroneal nerve or popliteal neurovascular lesions
- Peroneal nerve injuries are caused by stretching (neurapraxia); these will usually resolve over time.
- Arterial injuries frequently represent traction induced intimal injuries presenting as thrombosis; only rarely do they present as transection injuries secondary to laceration or avulsion.

**WHEN SURGERY IS INDICATED, STABILITY SHOULD ALWAYS BE EVALUATED UNDER ANESTHESIA!!!**



## Treatment




**The goal is the reconstruction of articular surface and limb alignment**



## Conservative treatment


- Indicated for nondisplaced or minimally displaced (<2 mm) fractures and in patients with advanced osteoporosis.
- Touch weight bearing and early range of knee motion in a hinged fracture-brace are recommended.
- Isometric quadriceps exercises and progressive passive, active-assisted, and active range-of-knee motion exercises are indicated.
- Touch weight bearing (10Kg) for 8 to 12 weeks is allowed, with progression to full weight bearing.






## Surgical treatment (ORIF)

Usually indicated in:

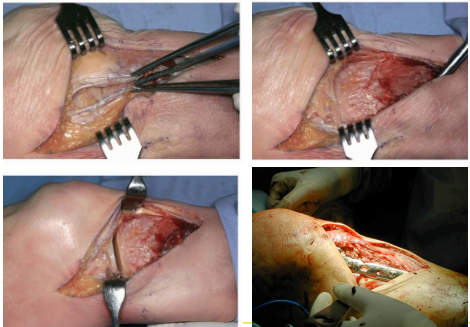

- More complex fracture patterns (Schatzker type II, IV to VI)
- Open fractures.
- Compartment syndrome.
- Associated vascular injury.
- Insufficient reduction with ARIF



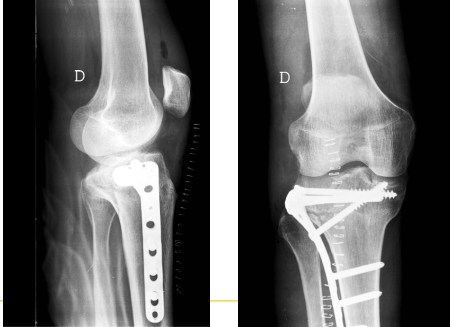

## Surgical treatment (ORIF)

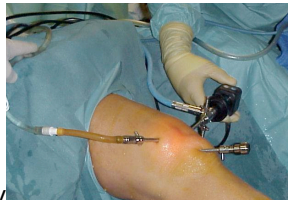## Surgical treatment (ORIF)

## Surgical treatment (ORIF)

### Surgical treatment (ARIF)




Usually indicated in:

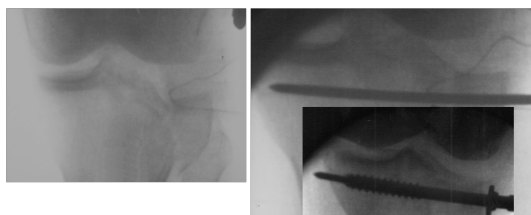
- Schatzker type I to IV
- To treat intrarticular lesions (menisci, loose bodies, ACL)
- To drain hemarthrosis



### Surgical treatment (ARIF)




### Surgical treatment (ARIF)



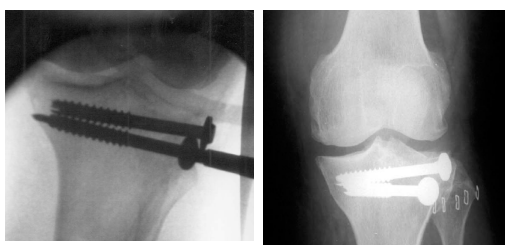“joystick technique” to reduce the wedge fragment



### Surgical treatment (ARIF)



### Surgical treatment (ARIF)



### Post-operative care (ARIF and ORIF)

- Non weight bearing with continuous passive motion and active range of motion.
- Weight bearing is allowed at 8 to 12 weeks.



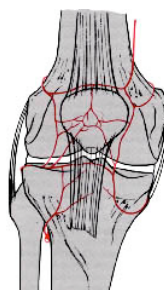
### Advantages of ARIF

- Mini-invasive
- Less post-operative pain
- Better visualization of the articular surface
- Debridement of loose bodies
- Diagnosis and treatment of intrarticular lesions
- Drainage of the hemarthrosis
- No need for lateral meniscus disinsertion



### Advantages of ARIF

- Respect of lateral tibial plateau vascularity



- Lateral superior genicular art.
- Lateral inferior genicular art.
- Anterior tibial recurrent art.

Hannouche D, Duparc F, Beaufile P, étude anatomique de la vascularisation du plateau tibial externe

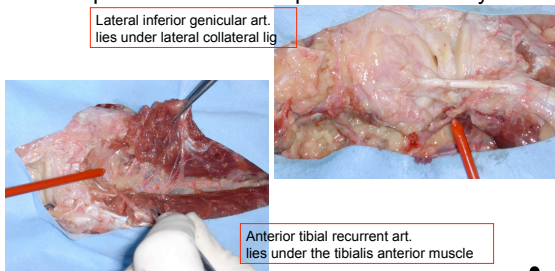
Ann Soc Franc d'Arthroscopie, 2000



### Advantages of ARIF

- Respect of lateral tibial plateau vascularity

Lateral inferior genicular art. lies under lateral collateral lig



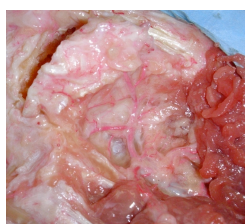Anterior tibial recurrent art. lies under the tibialis anterior muscle

Rossi R, Bonasia DE, Castoldi F. Arthroscopic Management of Fractures Around the Knee. McGinty 2010



### Advantages of ARIF

- Respect of lateral tibial plateau vascularity



Arterial anastomosis forms in front of lateral tibial plateau

Rossi R, Bonasia DE, Castoldi F. Arthroscopic Management of Fractures Around the Knee. McGinty 2010



### Disadvantages of ARIF

- Technically more demanding
- Saline leakage with
- Virtual risk of compartment syndrome (use gravity inflow)



### Results

- Both techniques reported comparable results
- No RCT comparing ARIF vs ORIF
- No studies evaluating the treatment for Split Fractures only

R. Rossi et al. / The Knee 15 (2008) 378–383



## Results for ARIF

AUTHOR, YEAR, REFERENCE	N° OF CASES	MEAN FOLLOW-UP (MONTHS)	FRACTURES TYPE	SCORES
Cassard, 1999	26	32,7	Schatzker type I to IV	Mean KSS score: 94.1 for pain, 94.7 for function
Gill, 2001	29	24	Schatzker type I to IV	Mean Rasmussen score: 27.5
Hung, 2003	31	36	Schatzker type I to VI	HSS scores: 25 excellent, 4 good, and 2 fair
Roche, 2001	15	33	Schatzker type I to VI	Rasmussen score: excellent in 80%, fair in 20%
Rossi, 2008	46	60	Schatzker type II and III	Knee Score: excellent in 80%, good 13%, fair in 7%



## Conclusions

- Stability should always be evaluated under anesthesia before and after fixation, and repairable associated lesions addressed
- ARIF and percutaneous screw fixation is indicated in closed split fractures
- Intrasubstance ACL/PCL lesion can be reconstructed after fracture healing
- Gravity inflow for ARIF
- ORIF is indicated in more complex cases, failed ARIF, in open fractures and compartment syndrome

